

Fungal Infections and Immune Deficiency

Rachna Shanbhag¹, Sagar Bhattad²

ABSTRACT

Fungal infections, also called mycoses, are important causes of mortality and morbidity in humans. Compromised immunity is the most important predisposing factor for clinically significant fungal infections. In this paper, the antifungal immune defense has been discussed and a simplified approach to immune deficiencies with increased susceptibility to fungi has been provided.

Keywords: *Candida*, Fungi, Immune deficiency, STAT1, STAT3.

Pediatric Infectious Disease (2021): 10.5005/jp-journals-10081-1304

INTRODUCTION

Fungal infections, also known as mycoses, are important causes of mortality and morbidity in humans. Fungal infections can be endemic while some are opportunistic. The endemic fungi form a part of our environment and their spores enter humans and cause infections. Opportunistic fungi may or may not cause disease in healthy individuals while they may infect and cause severe disease in immunodeficient persons. Therefore, deficiencies in the immune system make one prone to fungal infections.¹

ANTIFUNGAL IMMUNITY

The immune response to fungi involves both innate and adaptive immunity. Innate immune players like macrophages, neutrophils, and dendritic cells provide antifungal defense, while Th17 cells carry a pivotal antifungal role in the adaptive immune compartment.

Macrophages and Dendritic Cells

Macrophages and dendritic cells recognize fungal organisms via pattern recognition receptors that include toll-like receptors (TLRs) and lectin-like receptors called dectins. These activated dendritic cells then recruit naive T cells, which upon stimulation, get converted to Th17 helper cells (Fig. 1).

^{1,2}Division of Pediatric Immunology and Rheumatology, Department of Pediatrics, Aster CMI Hospital, Bengaluru, Karnataka, India

Corresponding Author: Sagar Bhattad, Division of Pediatric Immunology and Rheumatology, Department of Pediatrics, Aster CMI Hospital, Bengaluru, Karnataka, India, Phone: +91 9779433934, e-mail: drsagarbhattad@gmail.com

How to cite this article: Shanbhag R, Bhattad S. Fungal Infections and Immune Deficiency. *Pediatr Inf Dis* 2021;3(2):83–85.

Source of support: Nil

Conflict of interest: None

Th17 Cells

The Th17 cells (type of T helper cells) play an important role in handling fungal infections through IL-17 signaling. IL-17 pathway is critical for protection against mucosal candidiasis. Therefore, children presenting with recurrent *Candida* infections must be evaluated for Th17 pathway defects.²

Neutrophils

The neutrophils play a major role in defense against fungal infections through oxidative killing via the NADPH oxidase-dependent O₂⁻ production. Any defect in this mechanism makes

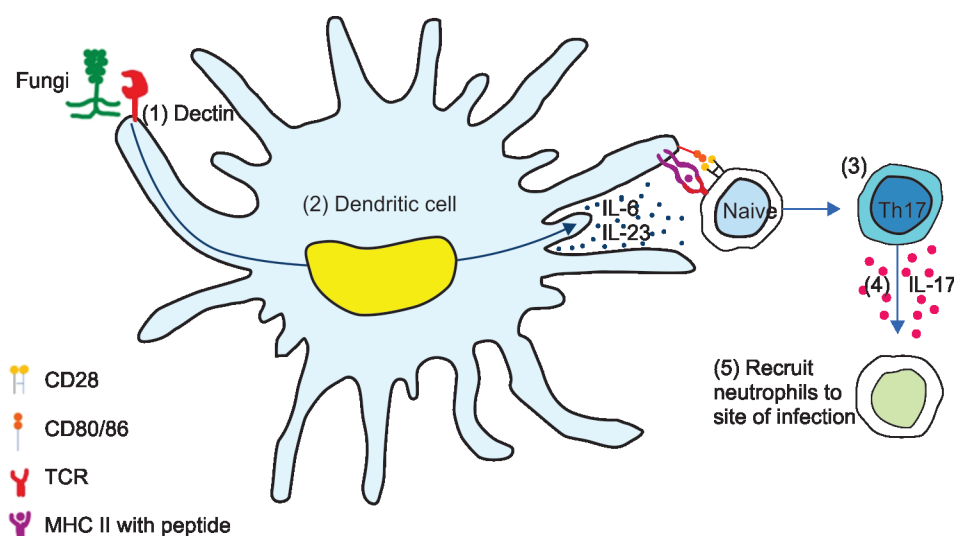


Fig. 1: Immune response to fungi

one susceptible to systemic candidiasis and invasive aspergillosis, as seen in patients with the chronic granulomatous disease (CGD).

Defects in any part of this pathway can predispose the patient to fungal infections. Patients with defects in Th17 cells develop mucocutaneous fungal infections, whereas those with neutropenia develop invasive fungal infections (Table 1).

Chronic Mucocutaneous Candidiasis (CMC)

These are a group of disorders characterized by increased susceptibility to *Candida* infections. Defects in the Th17 pathway are seen in most of them. These patients present with oropharyngeal candidiasis and/onychomycosis. They may also share susceptibility to other organisms (e.g., *Staphylococcus aureus*) based on the genetic defect.³ Chronic mucocutaneous candidiasis can be seen in the following diseases:

- CARD9 deficiency.
- STAT1 gain-of-function defect.
- AD hyper-IgE syndrome (STAT3 deficiency).
- AR hyper-IgE syndrome (DOCK8 deficiency).
- IL17RA and IL17F deficiency.
- APECED.

In the next section, we shall discuss few cases and try and understand how one can diagnose an immune deficiency in a patient presenting with fungal infections.

Case 1

A 9-year-old boy presented with recurrent episodes of pyoderma since 2 years of age and one episode of orbital abscess for which he had received antibiotics. Parents reported he had recurrent episodes of oral thrush from 3 years of age for which he had received multiple courses of oral fluconazole. Thrush would

Table 1: Immune deficiencies with increased predisposition to fungal infections

	Immune deficiency
A	Neutrophil defects Chronic granulomatous disease Congenital neutropenia Leukocyte adhesion deficiency (LAD1)
B	Th17 signaling defects CARD9 deficiency AD hyper-IgE (Jobs) syndrome (STAT3 deficiency) AR hyper-IgE syndrome (DOCK8 deficiency) STAT1 GOF mutation IL17RA deficiency IL17F deficiency APECED (autoimmune polyendocrinopathy, enteropathy, candidiasis, ectodermal dystrophy)
C	T-cell defects SCID (severe combined immune deficiency) X-linked hyper IgM syndrome Mendelian susceptibility to mycobacterial disease (defect in IFN γ signaling)
D	Defect in the fungal sensing mechanism CARD9 deficiency

AD, autosomal dominant; AR, autosomal recessive; GOF gain of function

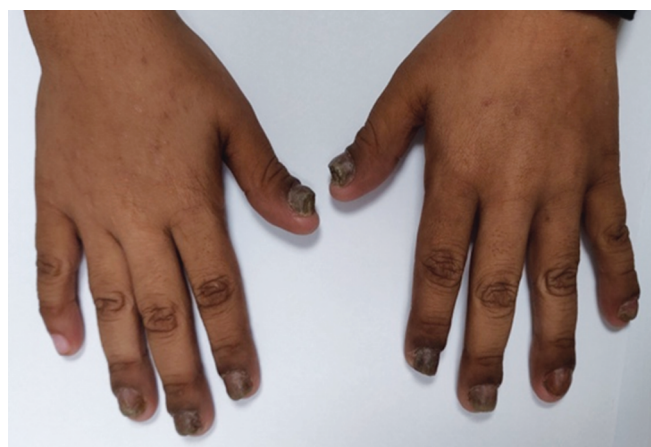

Fig. 2: Onychomycosis

improve transiently on antifungals and would recur on stopping therapy.

On examination, nails showed onychomycosis (Fig. 2).

Evaluation

Hemogram showed eosinophilia.

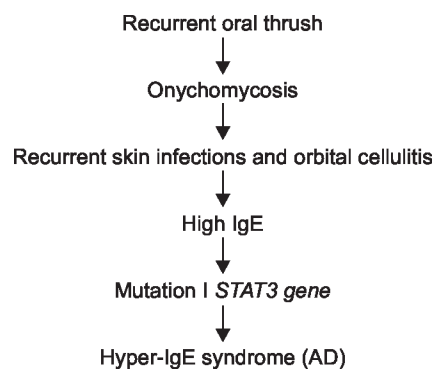
HIV test negative.

Serum immunoglobulins: IgE 3,800 IU/mL, IgG, IgA, and IgM—normal.

Genetic test: pathogenic mutation in STAT3 gene.

Diagnosis: hyper-IgE syndrome (AD).

Algorithm



Case 2

A 6-year-old girl was ventilated for severe community-acquired pneumonia and failed to respond to broad-spectrum intravenous antimicrobials. Contrast-enhanced computed tomography of the chest showed multiple nodules and bronchoalveolar lavage showed fungal hyphae suggestive of *Aspergillus*.

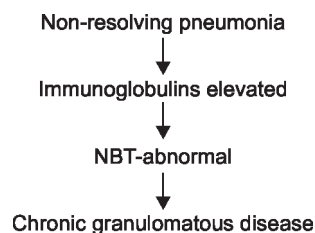
Diagnosis: *Aspergillus pneumonia*.

CBC: no neutropenia.

Immunoglobulins—elevated.

Nitroblue tetrazolium (NBT) dye reduction test and dihydrorhodamine (DHR) test were abnormal. These indicate a defect in the respiratory burst in neutrophils, suggestive of CGD.

Final diagnosis: CGD

Algorithm**Case 3**

A 6-month-old girl born to a third degree consanguineous couple presented with failure to thrive and persistent oral thrush. Previous two siblings had died at a young age (at 5 and 8 months of age). Both of them had had recurrent pneumonia, oral thrush, and had died of probable septicemia.

On examination, the index child was malnourished.

Evaluation: chest X-ray—the absence of thymic shadow, confirmed by USG of the neck.

CBC—Hb-7 g/dL, WBC-11,000/mm³ (N₈₆L₅M₅E₄), platelet count-130,000/mm³, ALC-550/mm³.

She had persistent lymphopenia!

Immunological tests were carried out:

IgG <131 mg/dL, IgA <35 mg/dL, IgM <22 mg/dL.

(Hypogammaglobulinemia noted).

Lymphocyte subsets—

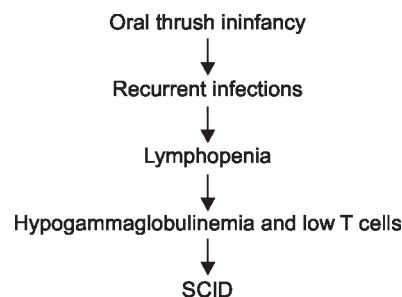
CD3-4% (50-70%)

CD19-94% (10-15%)

CD56-2% (5-10%)

In view of absent T cells and panhypogammaglobulinemia, a diagnosis of severe combined immune deficiency (SCID) was made. Presence of consanguinity and index child being a female, autosomal recessive inheritance was likely. T-B+NK-SCID can be seen in IL2RG defect (X-linked) and JAK3 deficiency (AR inheritance).

Hence, JAK3 deficiency was the likely cause of SCID in this family, which was confirmed by genetic tests.

Algorithm*Message*

- Patients presenting with repeated/unusual fungal infections must be evaluated for immune deficiency diseases.
- Recurrent or persistent candidiasis is an indicator of an underlying immune defect.
- Severe combined immune deficiency must be suspected in patients with recurrent candidiasis and lymphopenia in infancy.
- Patients with mucocutaneous candidiasis must be worked up for defects in Th17 cells or IL17 signaling defects.

REFERENCES

1. Badiee P, Hashemizadeh Z. Opportunistic invasive fungal infections: diagnosis & clinical management. *Indian J Med Res* 2014;139(2):195-204.
2. Mengesha BG, Conti HR. The role of IL-17 in protection against mucosal *Candida* infections. *J Fungi (Basel)* 2017;3(4):52. DOI: 10.3390/jof3040052.
3. Okada S, Puel A, Casanova JL, et al. Chronic mucocutaneous candidiasis disease associated with inborn errors of IL-17 immunity. *Clin Transl Immunol* 2016;5(12):e114. DOI: 10.1038/cti.2016.71.